

Femme de 84 ans adressée pour
IRM du mollet gauche pour
exploration d'un gros mollet

Doppler veineux sans
particularité

Dite Patrick, Liliane ...
féminin, 8001953017

50 mm
30003718156

ent: FFS
amen: IRM JAMBE...
rie: Cor T2FS

61,44
160,00

AM BROISE_PARE_Blite Patrick, Liliane ...
féminin, 8001953017

[27/02/201] mm
30003718156

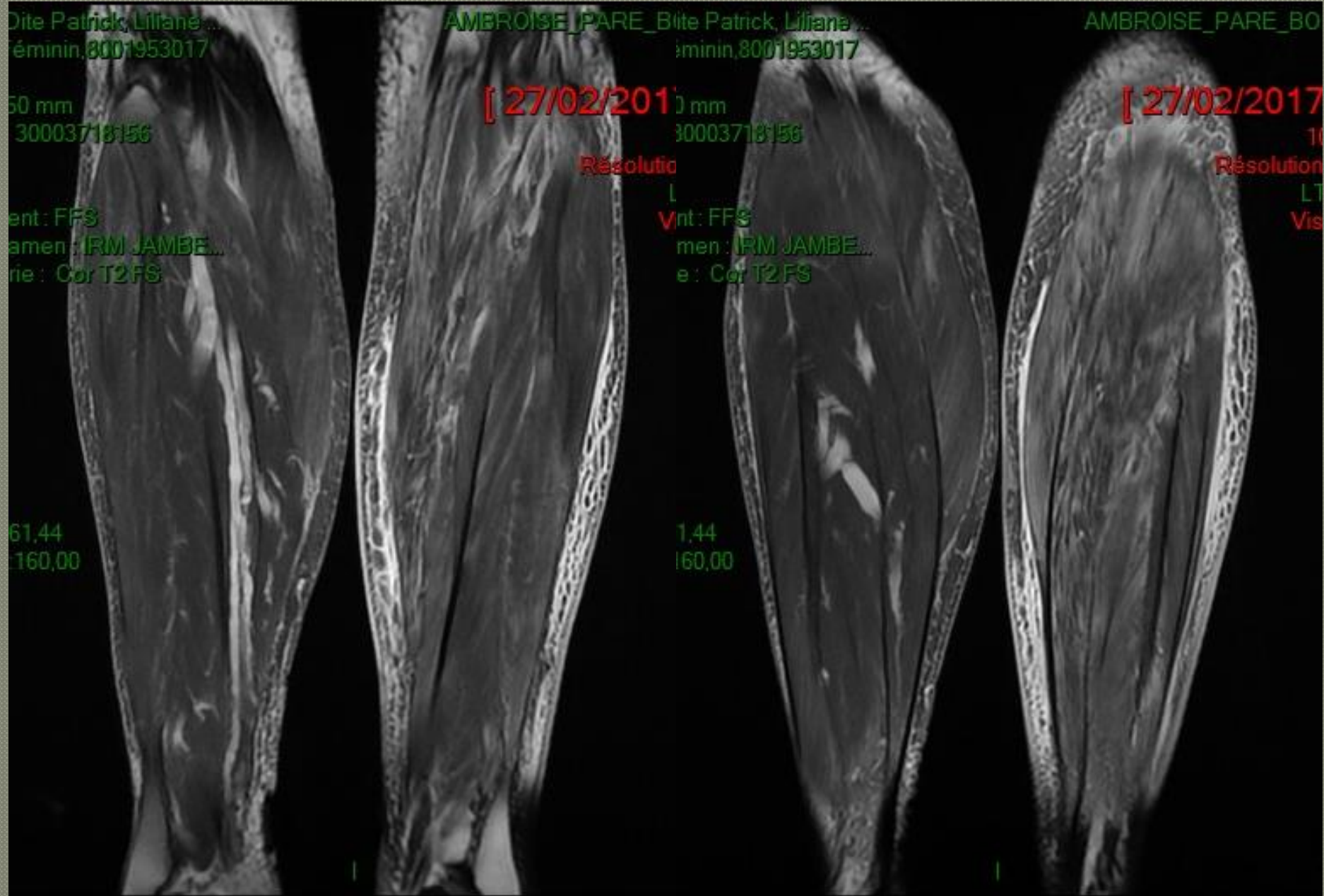
Résolutio
L
Vnt: FFS
men: IRM JAMBE...
e: Cor T2FS

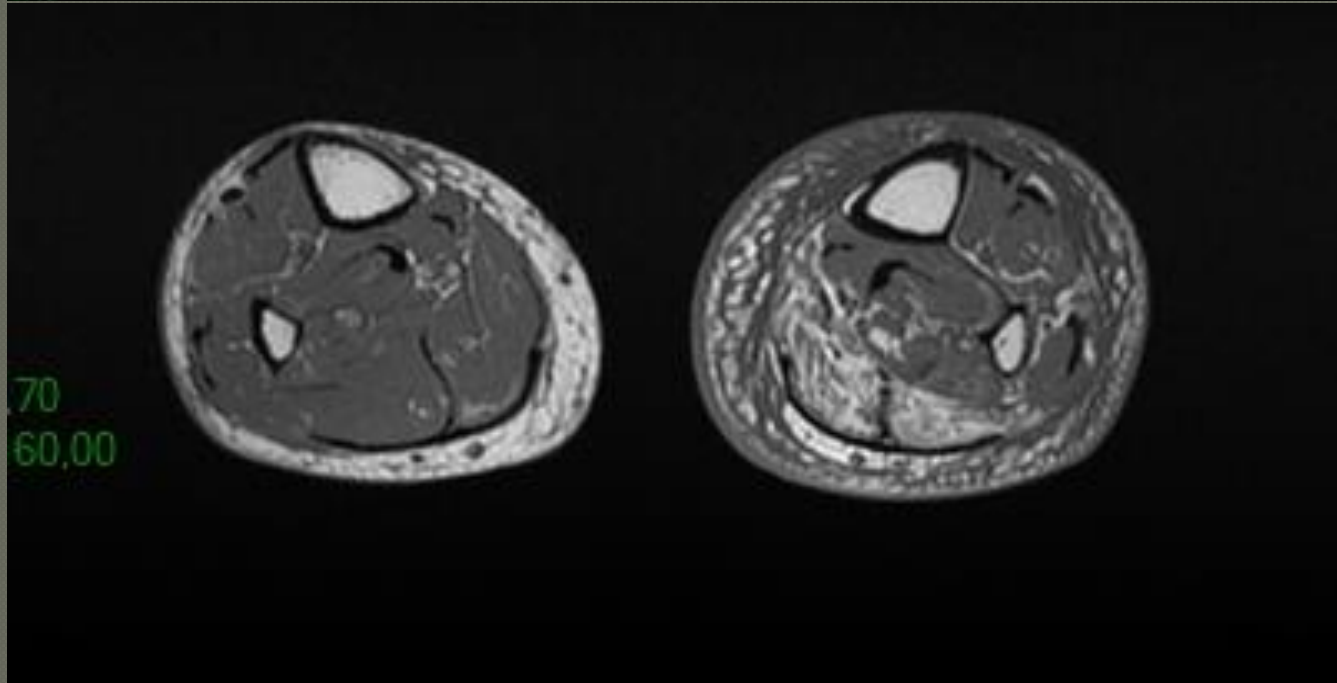
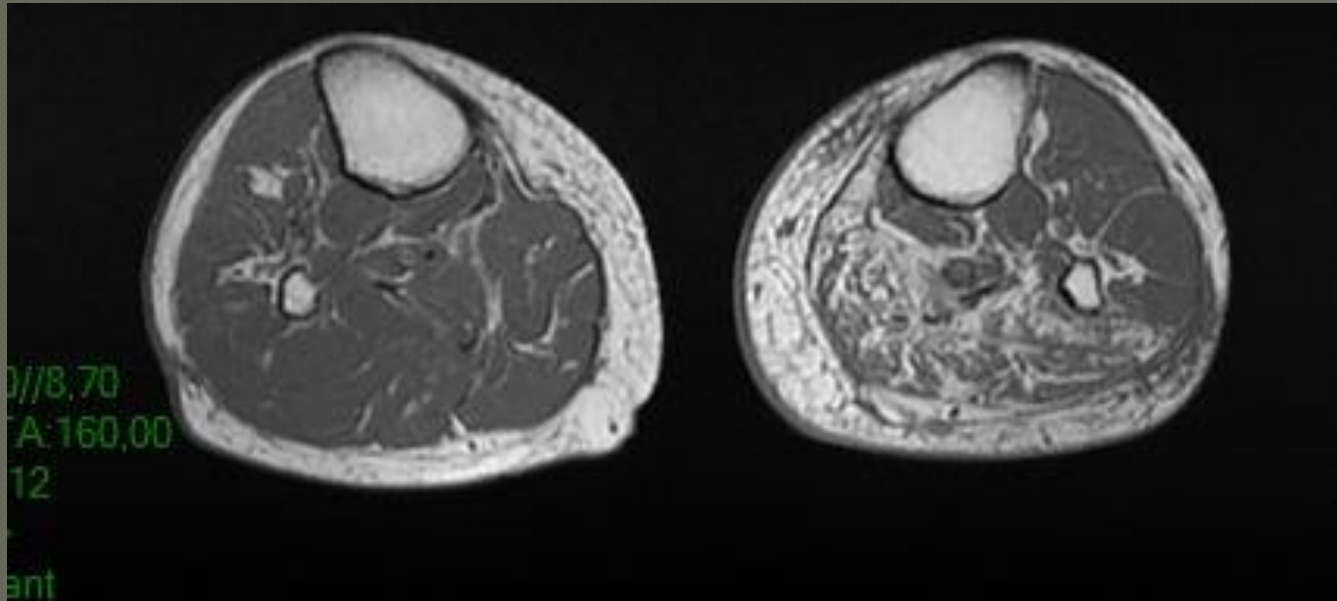
1,44
160,00

AM BROISE_PARE_BO

[27/02/2017

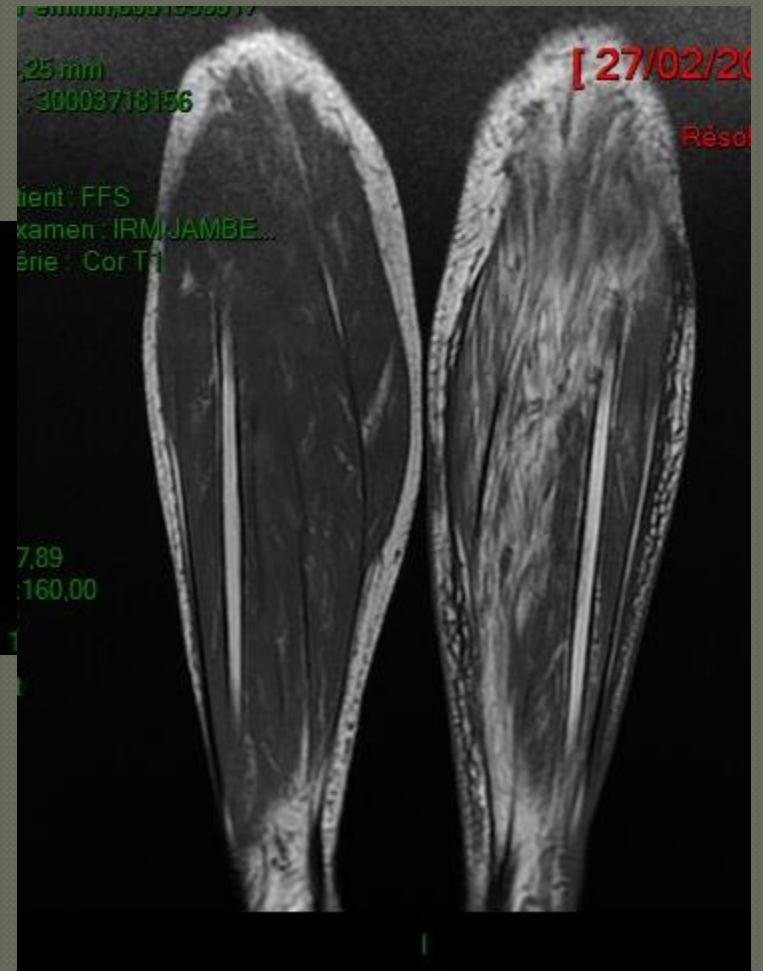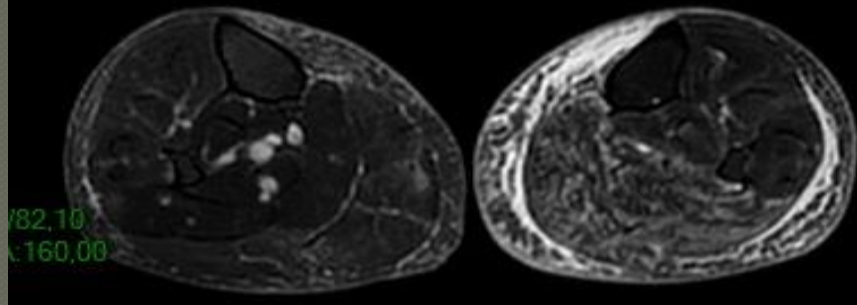
Résolution
LT
Vis

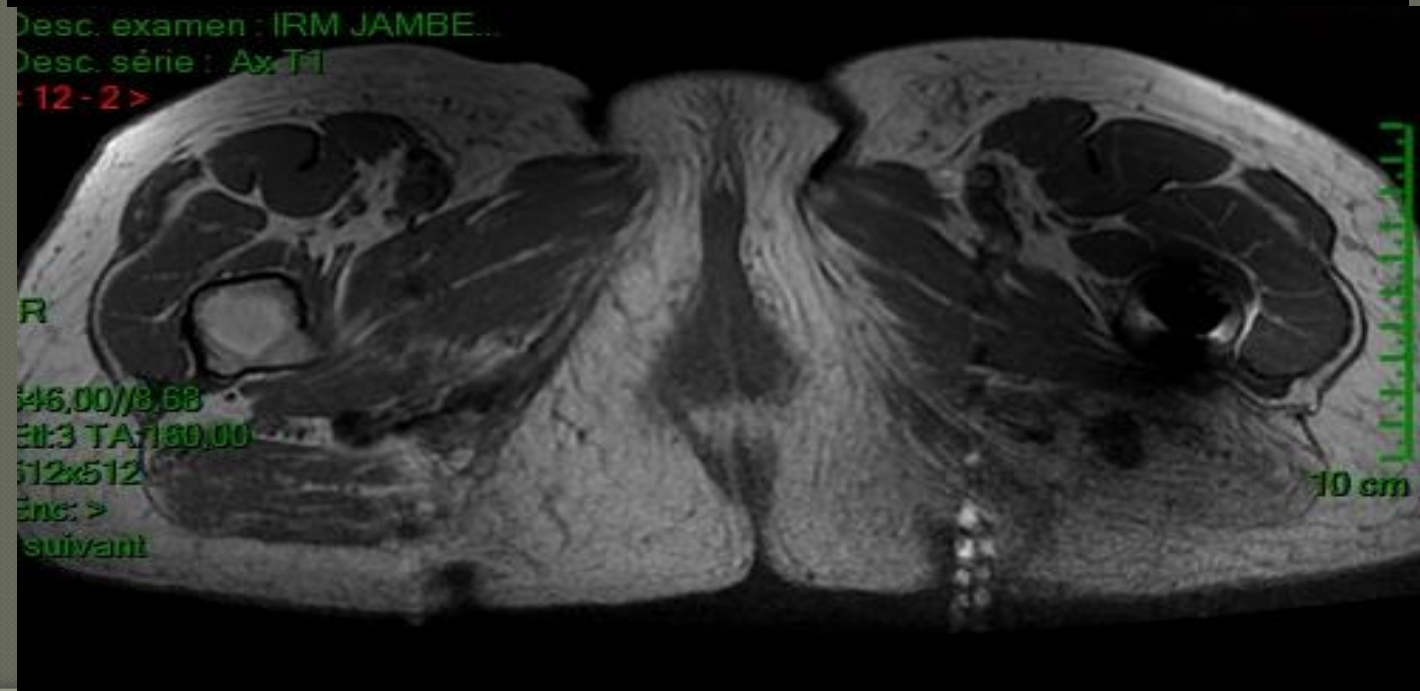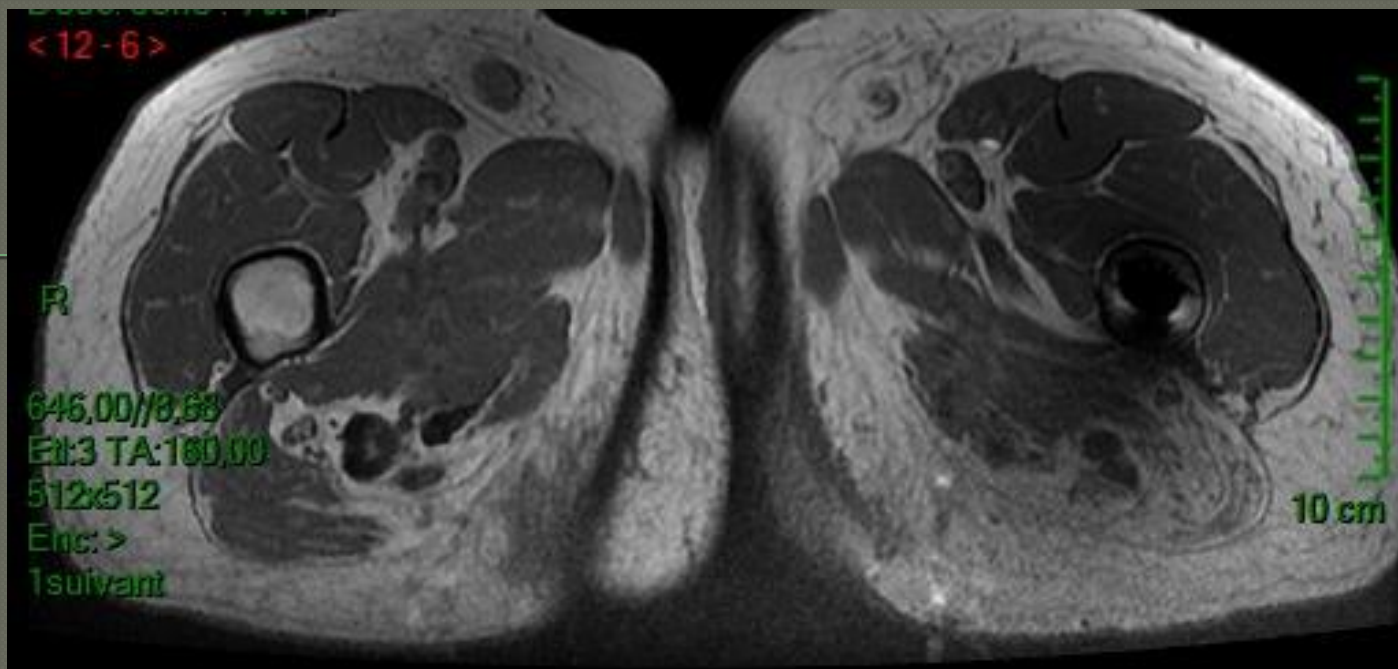


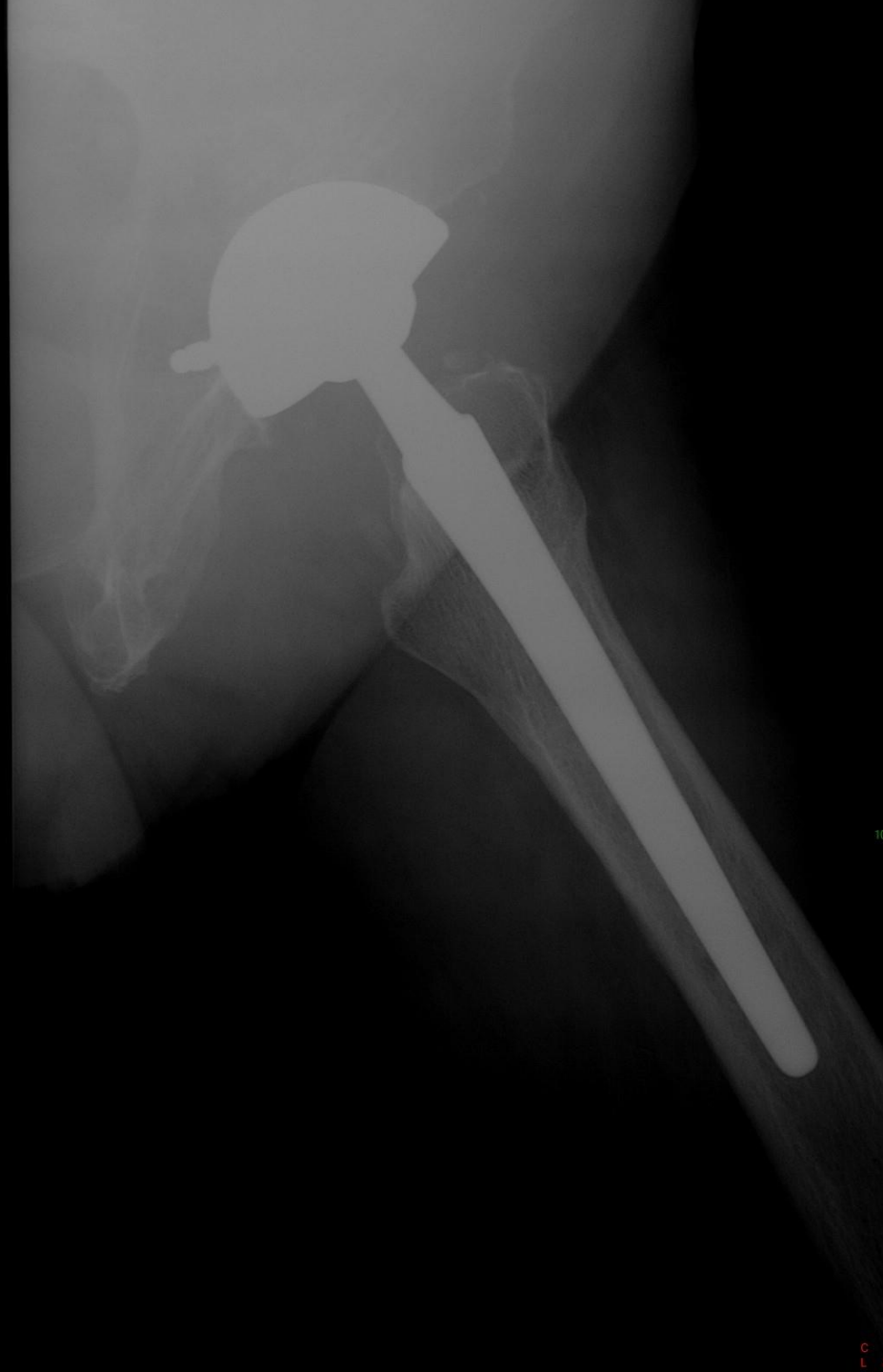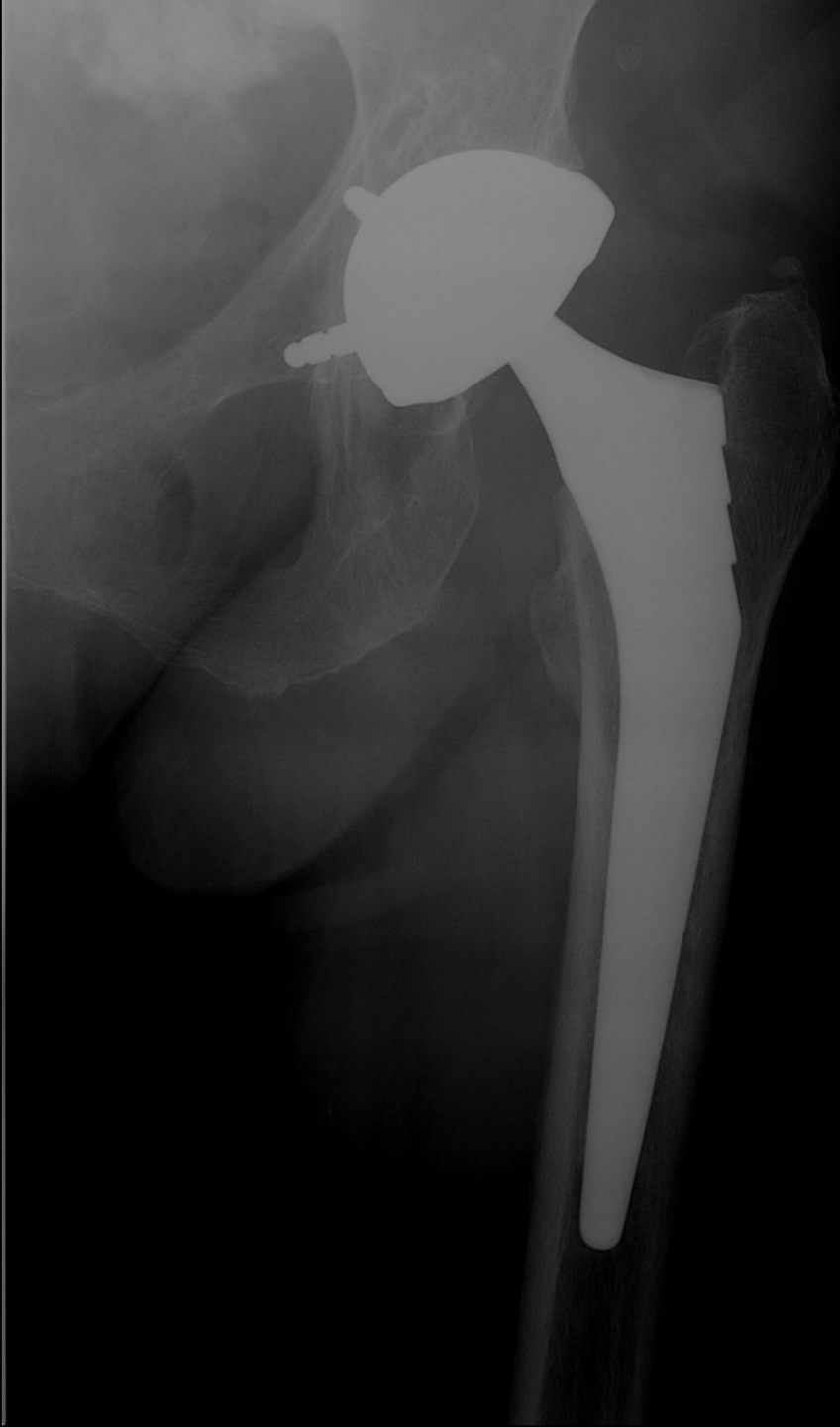


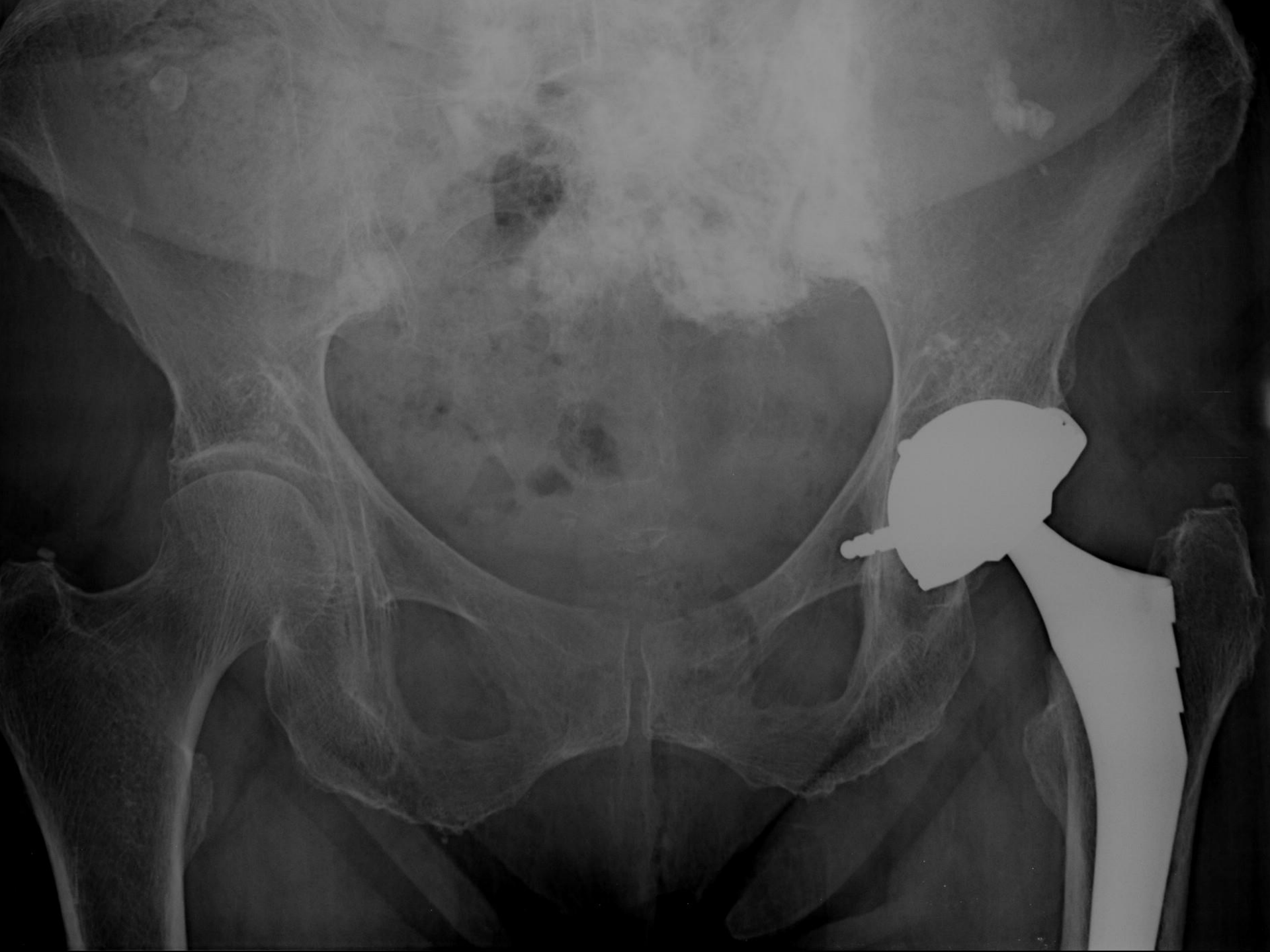HYPOTHESES? SUITE?

kamen : IRM JAMBE...
erie : AX T2 FS









DIAGNOSTIC
:SCIATIQUE
TRONCULAIRE POST
RADIQUE